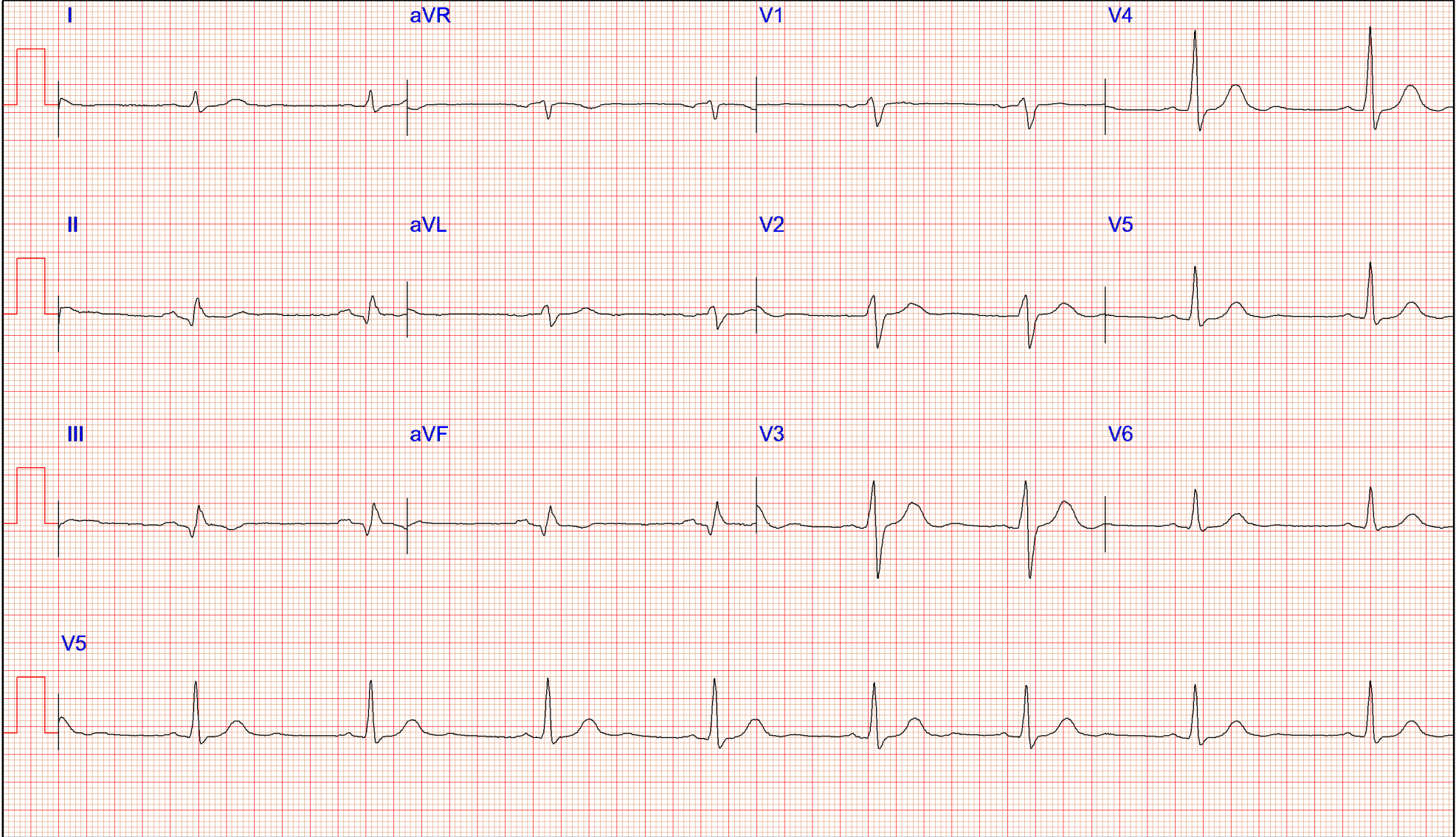


Hospital name
Hospital address
Signature:
Dr Smith
Technician Name: Tech Juddit

ID: **D_00012**
Last Name: **Anonymous**
First Name: **Polonyous**
Birth Date: **1/1/1936** Age: **53**
Sex: **M** Weight (kg): **67.0**

Non Confirmed Diagnosis:
age = 53; sex = male. sinus bradycardia. P: normal. QRS: inferior infarct. Q > 40 ms in aVF. with Q in II III. Q/R > 1/3 in aVF. marked intraventricular conduction delay. ST-T: normal. conclusion: abnormal ECG.

P(ms) = 128
PR(ms) = 180
QRS(ms) = 150
QT(ms) = 490
QTcB(ms)= 447
P Axis = 77
QRS Axis = 55
T Axis = 31
R-R(ms) = 1200



Record: [D_00012.RST] Modality: [Ecg Device(s/n 0)